

Clinical Imaging Alzheimer's Disease: Glaucoma Differential Diagnosis

Amy Falk, OD Denise A. Valenti, OD, FAAO

MCPHS University College of Optometry Worcester, MA

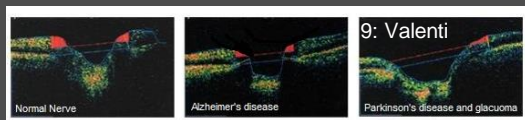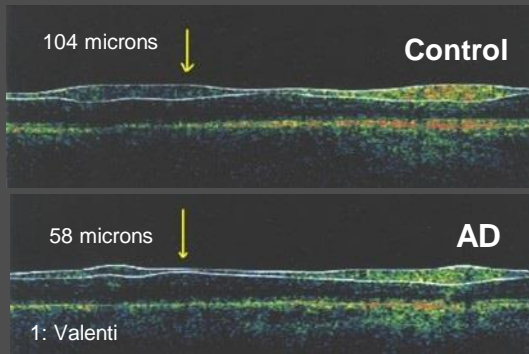
Amy.Falk@MCPHS.edu

Denise.Valenti@MCPHS.edu



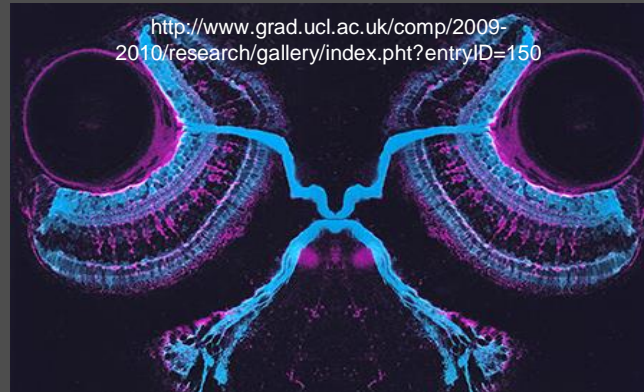OCT Imaging

Optical Coherence Tomography (OCT) is currently used in clinical settings for the diagnosis and management of glaucoma. OCT has shown significant reductions in the nerve fiber layer in those with Alzheimer's disease (AD) (1,2,3,4,8). OCT is similar to ultrasound but it does not touch the eye. Instead of sound waves, it utilizes light waves to generate images with a resolution of five microns. It is similar to having an eye photo taken.

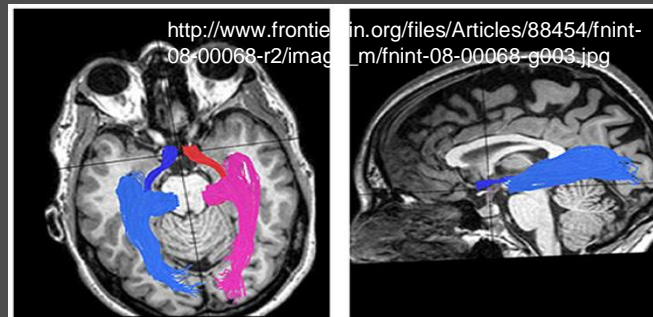


Alzheimer's disease, as well as other neurodegenerative diseases, impact the retina. Nerve fiber losses are accumulative if two diseases are present. (9)

Alzheimer's and Glaucoma Diffusion Tensor Imaging



Shown above is the relationship of retina neural tissue, retinal ganglion cells, nerve layers and axons to the brain in a zebra fish. The relationships hold true for humans. The losses in retina that occur in glaucoma are reflected within the brain. The losses in AD are reflected in the retina. DTI imaging has demonstrated losses in glaucoma and AD.(5) Below is a normal DTI.



Conclusions

AD and glaucoma both impact the visual pathways early in their disease processes. AD related damage originates primarily in the brain, including the visual association area-Brodmann 19. (8) The axonal loss is retrograde creating deficits in the optic nerve fiber layer axons and eventually loss of retinal ganglion cells. Glaucoma starts in the retina and optic nerve and impacts the visual pathways, including the visual association area. When the two diseases are present, the damage is greater. The visual losses in field, motion and contrast are greater. (9,10) Even with good acuity. It is important to have comprehensive ocular evaluations if there is a family history of disease impacting the visual pathways, including neurodegenerative diseases such as AD or glaucoma.

References

- 1.Valenti DA: *Neurology* 2007; 69: 1060.
- 2.Paquet C: *Neurosci letters* 2007; 420: 97-99.
- 3.Iseri PK: *J Neuro-ophthalmol* 2006; 26:18-24.
- 4.Bayhan HA *Clin ExpeOphthalmol* 2015; 43:145-51.
- 5.Nishioka CJ *Alzheimers Dis.* 2015; 45:97-107.
- 6.Wostyn P *Prog Retin Eye Res.* 2014; 39:107-8.
- 7.Marziani E *Invest Ophthalmol Vis Sci.*2013 :5953-8.
- 8.Valenti DA *Optometry.* 2010; 81:12-21 :12-21.
- 9.Valenti DA *Int J Alzheimers Dis.* 2010:793931.
- 10.Bayer AU *Eur Neurol.* 2002; 47:165-8.
- 11.Ghiso JA *J Glaucoma.* 2013; 22 Suppl 5:S36-8.
- 12.Sidek S *Eur J Radiol.* 2014; 83:1437-41.